

Pietro Felice, Vittorio Checchi, Roberto Pistilli, Antonio Scarano, Gerardo Pellegrino, Marco Esposito

Bone augmentation versus 5-mm dental implants in posterior atrophic jaws. Four-month post-loading results from a randomised controlled clinical trial

Key words *bovine anorganic bone, inlay graft, short dental implants, sinus lift, vertical augmentation*



Pietro Felice,
MD, DDS, PhD, Resident,
Department of
Periodontology and
Implantology, University of
Bologna, Bologna, Italy

Vittorio Checchi,
DDS, Research Fellow,
Department of
Odontostomatology,
Orthodontic and Surgical
Sciences, Second University
of Naples, Naples, Italy

Roberto Pistilli,
MD, Resident, Oral and
Maxillofacial Unit, San
Filippo Neri Hospital, Rome,
Italy

Antonio Scarano,
DDS, Researcher, University
of Chieti, Italy

Gerardo Pellegrino, DDS,
Oral Surgery &
Implantology Fellow,
Department of Oral and
Dental Sciences, University
of Bologna, Bologna, Italy

Marco Esposito,
DDS, PhD, Senior Lecturer,
Oral and Maxillofacial
Surgery, School of Dentistry,
The University of
Manchester, UK and
Associated Professor,
Department of Biomaterials,
The Sahlgrenska Academy
at Göteborg University,
Sweden

Correspondence to:
Dr Marco Esposito, School
of Dentistry, Oral and
Maxillofacial Surgery,
The University of
Manchester,
Higher Cambridge Street,
Manchester, M15 6FH.
E-mail: espositomarco@
hotmail.com

Purpose: To evaluate whether short (5 mm) dental implants could be a suitable alternative to augmentation and placement of longer implants (10 mm) in posterior atrophic jaws.

Materials and methods: Thirty partially edentulous patients with bilateral posterior edentulism were included: 15 patients having 5 to 7 mm of residual crestal height above the mandibular canal, and 15 patients having 4 to 6 mm of residual crestal height below the maxillary sinus and bone thickness of at least 8 mm measured on a CT scan. The patients were randomised either to receive one to three submerged 5-mm-long Rescue implants (Megagen) or 10-mm-long Rescue implants placed in augmented bone according to a split-mouth design. Mandibles were augmented with interpositional anorganic bovine bone blocks (Bio-Oss) and maxillae with granular Bio-Oss placed through a lateral window under the lifted sinus membrane. Resorbable barriers were used to cover the grafted sites. Grafts were left to heal for 4 months before placing the implants using a submerged technique. Four months after implant placement, provisional reinforced acrylic prostheses were delivered and replaced 4 months later by definitive screw-retained metal-ceramic prostheses. Outcome measures were: prosthesis and implant failures, any complications, time needed to fully recover mental nerve function (only for mandibular implants) and patient preference assessed 1 month after loading. All patients were followed up to delivery of the final restorations (4 months after loading).

Results: A systematic deviation from the research protocol occurred: the operator used another implant system (EZ Plus, Megagen) 10 mm or longer with a diameter of 4 mm at the augmented sites. No patients dropped out. In 5 patients of the augmented group (all mandibles) there was not enough height to place 10-mm-long implants as planned and shorter implants (7 and 8.5 mm) were used instead. In each group, one prosthesis could not be placed when planned because an implant was found to be mobile at abutment connection: one 5 mm maxillary implant and one 8.5 mm mandibular implant in the augmented group. Five complications occurred: two in the augmented group (one maxillary sinus perforation and one mandibular wound dehiscence after implant placement possibly associated with the failure of one implant) versus three maxillary sinus perforations in the 5-mm-long implant group. The difference was not statistically significant. No patient suffered from permanent disruption of alveolar inferior nerve function, however, significantly more patients had a paraesthesia up to 3 days in the augmented group. There was no statistically significant difference in patient preference with the majority of patients expressing no preference for which treatment they received, finding both of them acceptable.

Conclusions: With residual bone height of 5 to 7 mm over the mandibular canal, short 5 mm implants might be preferable to vertical augmentation since the treatment is faster, cheaper and associated with less morbidity. In the presence of 4 to 6 mm of bone height below the maxillary sinus it is still unclear which procedure could be preferable. These preliminary results must be validated by a follow-up of at least 5 years.

■ Introduction

Partial edentulism of posterior jaws is a common problem. The missing dentition can be replaced by partial removable dentures though they are poorly tolerated because of their instability and discomfort. The ideal solution would be an implant-supported fixed prosthesis. Unfortunately, posterior jaws often have insufficient bone height to place dental implants of 'adequate' length due to anatomical limitations such as the inferior alveolar nerve or a pneumatized maxillary sinus. Ten to 12 mm of bone height of adequate thickness is generally considered sufficient to allow placement of dental implants of length (9 to 11 mm) sufficient to guarantee a good long-term prognosis of an implant-supported prosthesis^{1,2}. Unfortunately, often the residual amount of bone in posterior jaws is less than 10 mm, therefore the long-term prognosis of prostheses supported by short implants is considered a higher risk of failure¹.

In these situations, the dentist is faced with the dilemma of whether to augment the bone or to use short implants (8 mm or less). Various techniques are currently used to augment the posterior mandibles³ and maxillae⁴. Few of these techniques have been tested in randomised clinical trials. The techniques used for vertically augmenting posterior mandibles are various vertical guided bone regeneration (GBR) procedures⁵⁻⁸, alveolar distraction osteogenesis^{5,6}, onlay bone grafting⁶, and the use of interpositional bone grafts^{9,10}. Various sinus lift procedures to augment posterior maxillae¹¹⁻¹⁸ have also been evaluated.

There is a large variation in augmentation procedures, with materials and biologically active factors used in many combinations, but the evidence of the superiority of a certain technique/material over any other is still lacking^{3,4}. It appears, however, that bone substitutes can be successfully used as an alternative to autogenous bone^{3,8,10,12,19} since patient discomfort

is reduced. Other general limitations of augmentation procedures are that they are technically demanding and therefore require skilful operators, are often associated with significant postoperative morbidity and complications, can be expensive, and may require a long time (up to 1 year) before patients are able to chew on their implant-supported prostheses⁴.

Implant lengths of 7 mm or shorter may not have a good long-term prognosis when compared with longer implants¹, however, short implants could be a simpler, cheaper and faster alternative to augmentation procedures of the posterior jaws. The definition of 'short' implants is controversial since some authors consider as 'short' all those implants with a length ranging between 7 and 10 mm¹ whereas other authors consider 'short' those implants with a designed intra-bony length of 8 mm or less². Implants with lengths varying from 5 to 8 mm are currently used, and there are only a few short-term comparative studies evaluating their efficacy in a reliable way^{16,19}. The preliminary results of these randomised controlled clinical trials (RCT) suggest that implants 7 to 8 mm long can be a better alternative to augmentation procedures, however there is no study evaluating even shorter implants such as those only 5 mm long.

The aim of this RCT was to compare the outcome of partial fixed prostheses supported by implants 5 mm long (Rescue™ implant with internal connection, MegaGen, Gyeongbuk, South Korea) with prostheses supported by longer implants (10 mm) placed in posterior jaws augmented either with a mandibular interpositional block of anorganic bovine bone (Bio-Oss®, Geistlich Pharma, Wolhusen, Switzerland) or with granular Bio-Oss placed through a lateral window below the lifted maxillary membrane.

The present investigation is a preliminary report focussing on outcomes up to the insertion of the final prosthesis 4 months after loading. It was planned to

follow up the patients to the fifth year of function in order to evaluate the success of the procedures over time. The present article is reported according to the CONSORT statement for improving the quality of reports of parallel-group randomised trials (<http://www.consort-statement.org/>).

■ Materials and methods

Any partially edentulous patient having bilateral edentulism in posterior jaws (premolars and molars) with a similar degree of bone resorption requiring one to three implants 5 mm long being 18 years or older, and able to sign an informed consent form was eligible for the present trial. The vertical bone height at the implant sites had to be in the range of 5 to 7 mm in mandibles (Fig 1), 4 to 6 mm in maxillae (Fig 2) and bone thickness of at least 8 mm measured on a preoperative computer tomography (CT) scan.

Patients with the following were excluded from the trial:

- general contraindications to implant surgery
- subjected to irradiation of the head and neck area
- immunosuppressed or immunocompromised
- treated or under-treatment with intravenous amino-bisphosphonates
- active periodontitis, poor oral hygiene and motivation
- uncontrolled diabetes
- pregnant or nursing
- substance abusers
- psychiatric problems or unrealistic expectations
- lack of opposite occluding dentition in the area intended for implant placement
- acute or chronic infection/inflammation in the area intended for implant placement
- participating in other trials, if the present protocol could not be properly followed
- referred only for implant placement
- extraction sites with less than 3 months of healing.

Patients were grouped into three groups according to what they declared: non-smokers, light smokers (up to 10 cigarettes per day) and heavy smokers (more than 10 cigarettes per day). Patients were recruited and treated in different private practices and two hospitals

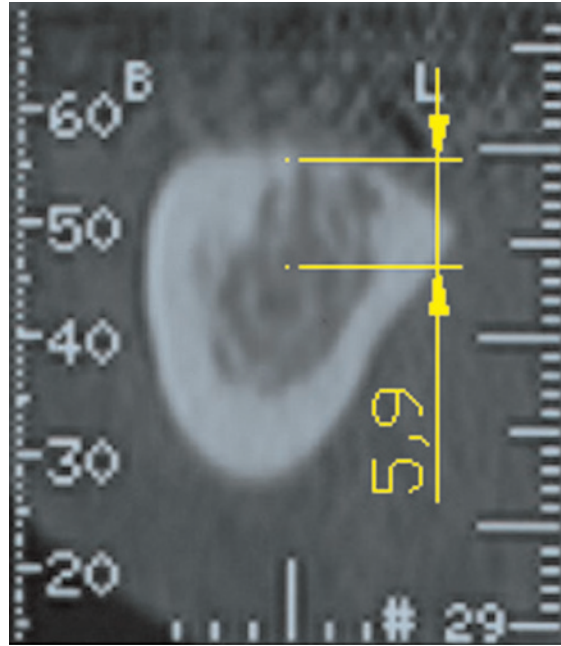


Fig 1 Preoperative CT scans used to screen eligibility of patients with bilateral atrophic posterior mandible: 5 to 7 mm of bone height and at least 8 mm thick above the nerve canal was required.

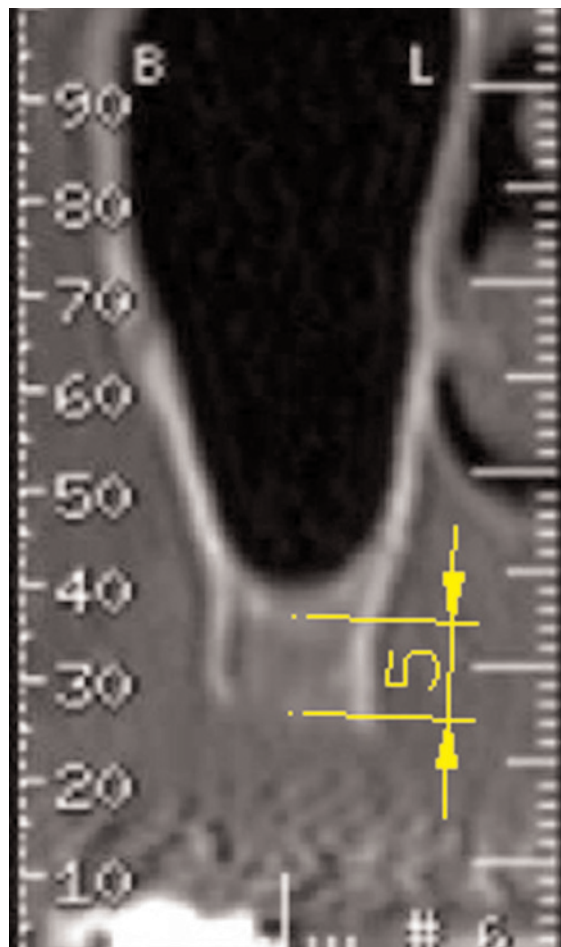


Fig 2 Preoperative CT scans used to screen eligibility of patients with bilateral atrophic posterior maxilla: 4 to 6 mm of bone height and at least 8 mm thick below the maxillary sinus was required.

but were treated by the same operator (PF performed all of the surgical procedures), following similar and standardised procedures.

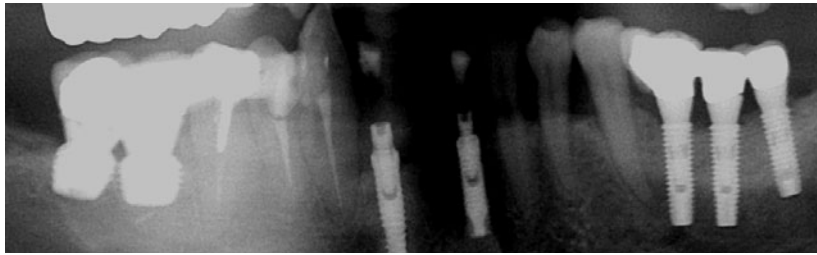


Fig 3 Panoramic radiograph of a patient randomised according to a split-mouth design to receive 5 mm long and 6 mm wide Rescue implants on one side and longer EZ Plus implants in bone vertically augmented with an interpositional Bio-Oss block on the other side of the mandible.



Fig 4 Panoramic radiograph of a patient randomised according to a split-mouth design to receive 5 mm long and 6 mm wide Rescue implants on one side and longer EZ Plus implants in the maxillary sinus augmented with 100% granular Bio-Oss on the other side.

The principles outlined in the Declaration of Helsinki on clinical research involving human subjects were adhered to. All patients received thorough explanations and signed a written informed consent form prior to being enrolled in the trial. After consent was given, eligible patients were randomised according to a split-mouth design to receive either 5-mm-long implants (test procedures) or an interpositional block of anorganic bovine bone (Bio-Oss, Geistlich Pharma) in mandibles (Fig 3) or 100% granular Bio-Oss in maxillary sinus to allow placement of identical implants 10 mm long (Fig 4). The side randomised to the augmentation procedure was treated first. Implants were placed at both sites during the same surgical session, 4 months after the augmentation procedure.

■ Augmentation procedure

Study models were used to plan the amount of vertical augmentation required by the patients at both mandibular sites. Within 10 days prior to bone augmentation and implant placement, all patients underwent at least one session of oral hygiene instructions and professionally delivered debridement when required, and 1 minute rinsing with 0.2% chlorhexidine mouthwash twice a day was prescribed.

All patients received prophylactic antibiotic therapy: 2 g of amoxicillin (or clindamycin 600 mg if allergic to penicillin) 1 hour prior to augmentation and rinsed for 1 minute with 0.2% chlorhexidine mouthwash. All patients were treated under local anaesthesia using articaine with adrenaline 1:100.000. No intravenous sedation was used.

For the mandible, a surgical template was used to indicate the planned implant positions (Fig 5). A paracrestal incision was made through the buccal area, respecting the emergence of the mental nerve, to expose the alveolar ridge (Fig 6). A mucoperiosteal flap was carefully retracted, trying to avoid tension on the mental nerve. A horizontal osteotomy was made approximately 2 to 4 mm above the mandibular canal using piezosurgery (Mectron Piezosurgery® device, Mectron, Carasco, Genoa, Italy). Two oblique cuts were then made in the coronal third of the mandibular bone with the mesial cut at least 2 mm distal to the last tooth in the arch. The height of the osteotomised segment has to be at least 3 mm to allow the insertion of the stabilising screws without fracturing. The segment was then raised in a coronal direction sparing the lingual periosteum (Fig 7), Bio-Oss blocks were modelled to completely fill the sites to the desired height and shape (Fig 8), interposed between the raised fragment and the mandibular basal bone (Fig 9), and fixed with titanium miniplates and miniscrews (Gebrüder Martin, Tuttlingen, Germany) (Fig 10) to both the basal bone and the osteotomised crestal bone. Gaps in the vertical osteotomies were filled with particulated Bio-Oss from the blocks. The grafted areas were covered with a resorbable barrier (Bio-Gide®, Geistlich Pharma) (Fig 11). Periosteal incisions were made to release the flaps as coronally as needed.

For maxillae, a crestal incision was made, and after flap elevation a lateral window was prepared with piezosurgery (Mectron) and carefully displaced internally after elevation of the maxillary membrane (Fig 12). The sinus was loosely packed with granular Bio-Oss (Fig 13) and the lateral window was covered with a resorbable Bio-Gide barrier (Fig 14).

Flaps were sutured with Vicryl 4.0 sutures (Ethicon FS-2, St-Stevens-Woluwe, Belgium), until the incisions were perfectly sealed. Ice packs were provided, amoxicillin 1 g (or clindamycin 300 mg) was prescribed to be taken twice a day for 7 days. Ibuprofen 400 mg was prescribed to be taken 2 to 4 times a day during meals,

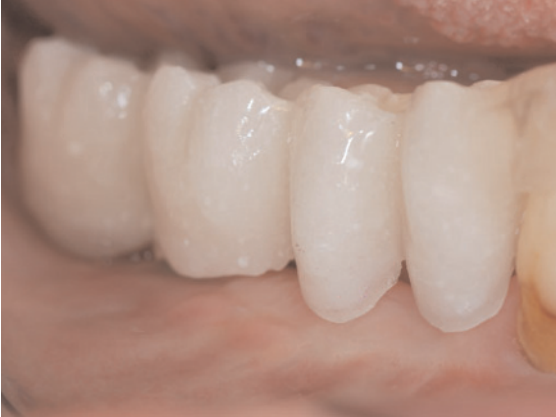

Fig 5 A surgical template used in the mandible to indicate the planned position of the implants.

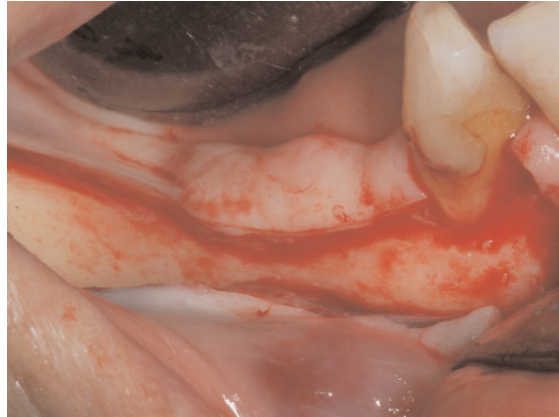


Fig 6 A paracrestal incision was made on the mandibular buccal side.

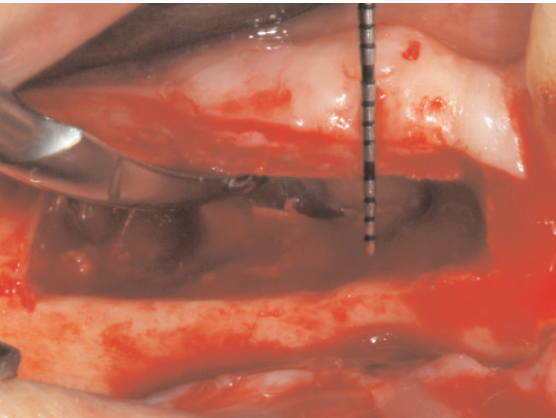


Fig 7 After horizontal and vertical osteotomies were made, sparing the lingual periosteum, the cranial osteotomised segment was moved upward.

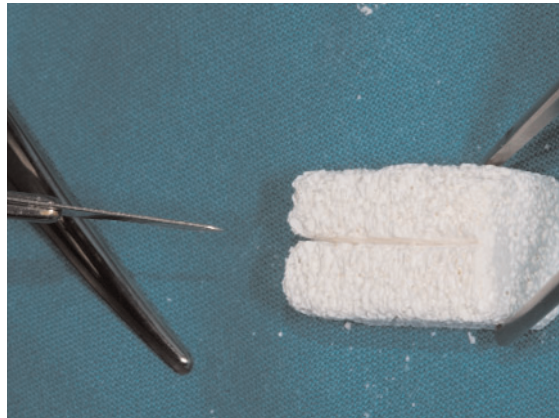


Fig 8 The block of anorganic bovine bone (Bio-Oss) was trimmed and shaped to be fitted between the basal bone and cranial segments.

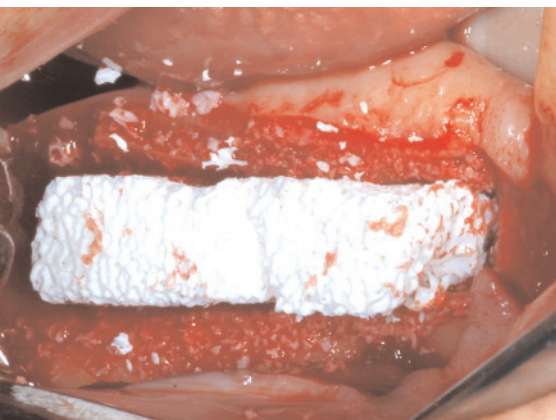


Fig 9 The Bio-Oss block was inserted as an interpositional graft.

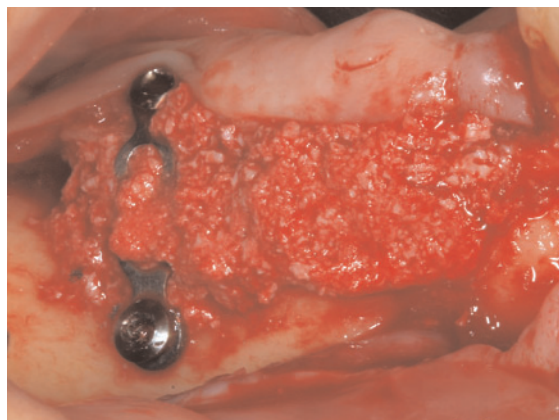

Fig 10 The graft was fixed with miniplates and screws.

as long as required. Patients were instructed to use Corsodyl gel 1% twice a day for 2 weeks, to have a soft diet for 1 week, and to avoid brushing and trauma on the surgical sites. No removable prosthesis was

allowed for 1 month. Patients were seen after 3 days and sutures were removed after 10 days. All patients were recalled for additional post-operative check-ups 1, 2 and 3 months after the augmentation procedure.

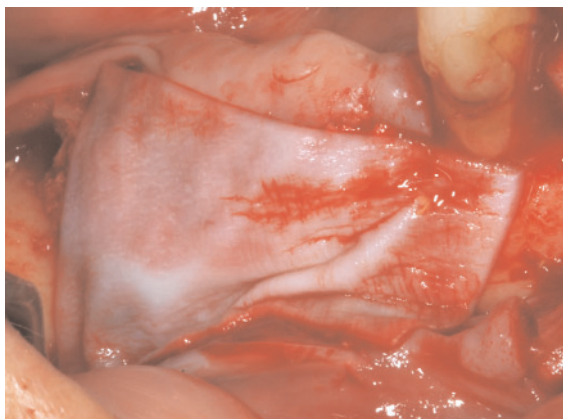

Fig 11 A resorbable collagen membrane was used to cover the graft material.

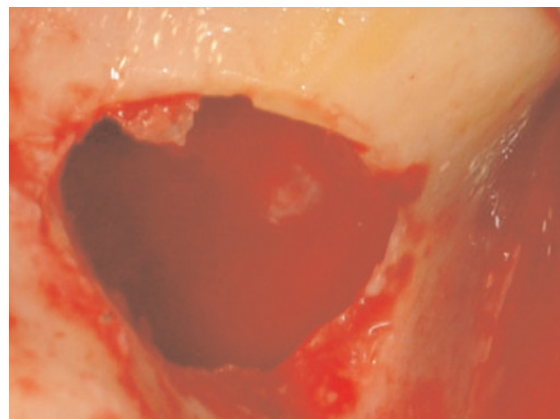


Fig 12 In the maxilla, after crestal incision and after flap elevation, a lateral bony window was prepared with piezosurgery and displaced internally after elevation of the maxillary lining.

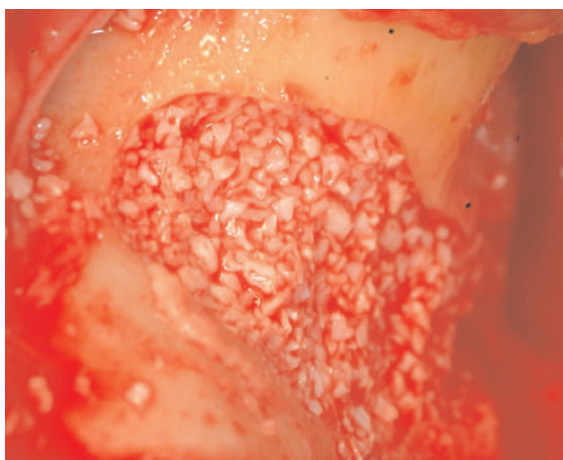


Fig 13 The sinus was loosely packed with 100% granular Bio-Oss.

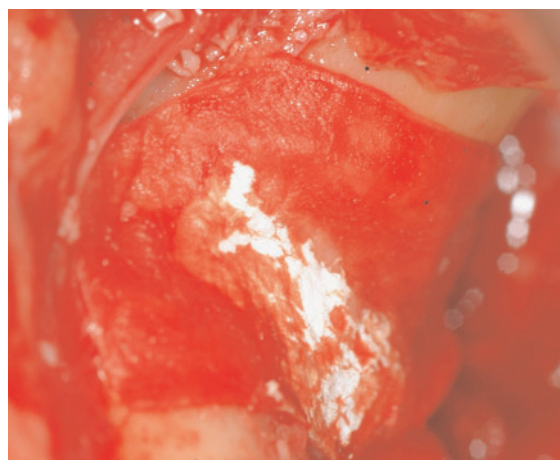


Fig 14 The lateral window was covered with a resorbable Bio-Gide barrier.

■ Implant placement

Four months after augmentation CT scans were taken to assess bone volumes for planning implant surgery. A total of 2 g of amoxicillin (or **clindamycin** 600 mg) was administered 1 hour prior to implant placement and patients rinsed for 1 minute with chlorhexidine mouthwash 0.2%. Infiltration anaesthesia (articaine with adrenaline 1:100.000) was used in both the mandible and maxilla. Both sites were treated at the same surgical session. After crestal incision and flap elevation, miniplates were removed, and knife edge ridges were flattened to reach a thickness of at least 8 mm (Fig

15). One to three 5 mm long and 6 mm in diameter (short implant group) (Fig 16) or 10 mm long and 6 mm in diameter implants (augmented group) (Fig 17) were to be inserted under prosthetic guidance using a surgical template. Only 5 to 10 mm long Rescue (Megagen) dental implants, with a diameter of 6 mm, with internal connection made of commercially pure titanium with a surface blasted with hydroxyapatite particles and cleaned with acid were to be used according to the original protocol. However, the operator correctly used 5 mm long Rescue implants in the test group, and EZ Plus Megagen implants with internal connection of varying lengths (10, 11.5 and 13 mm),

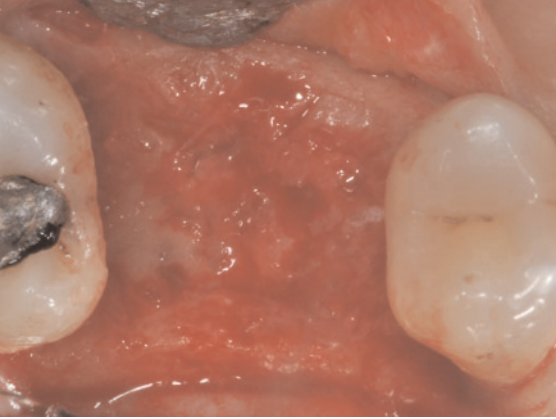


Fig 15 After crestal incision and flap elevation, miniplates were removed and knife edge ridges were flattened to reach a thickness of at least 8 mm.

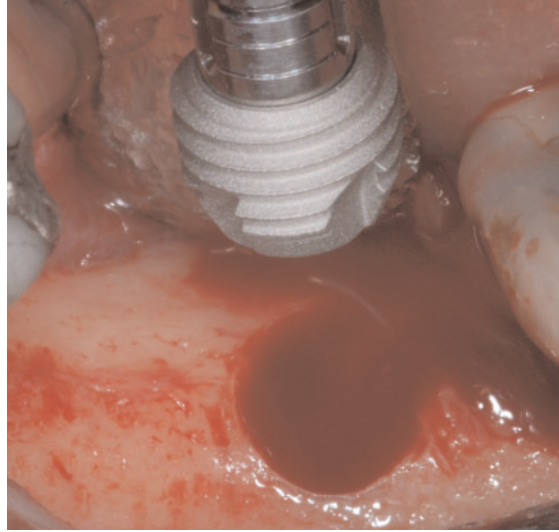


Fig 16 One to three 5 mm long and 6 mm in diameter Rescue implants were inserted in the non-augmented bone.

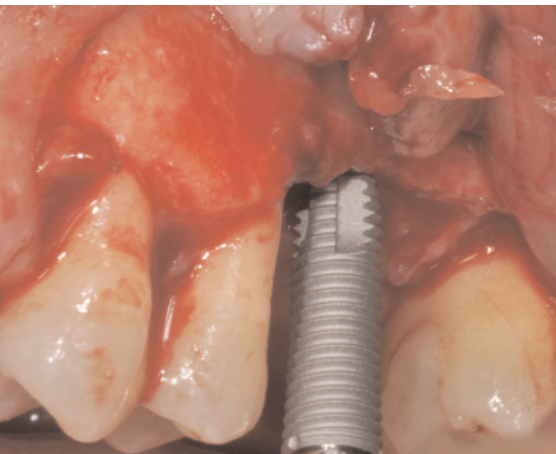


Fig 17 One to three 8.5 to 13 mm long 4 mm wide EZ Plus implants were inserted in the augmented bone. The original protocol required the placement of 10 mm long (or shorter if necessary) 6 mm wide Rescue implants also at the augmented sites.

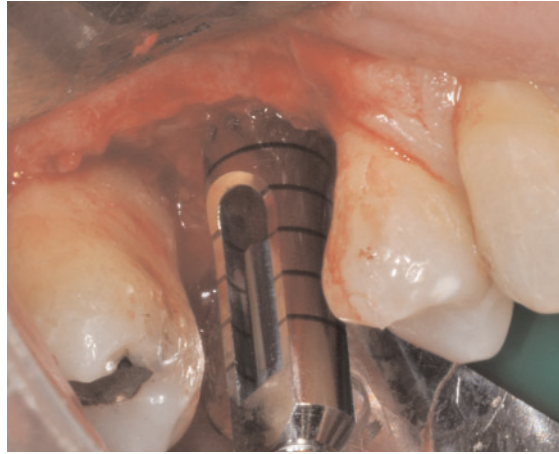


Fig 18 A trephine bur with an external diameter of 5 mm was used as initial bur for preparing the osteotomy sites for the Rescue short implants following the protocol recommended by the manufacturer.

all with a diameter of 4 mm, at augmented sites (Fig 17). Obviously the operator was allowed to use shorter implants (7 and 8.5 mm) at augmented sites if the augmentation was not completely successful. The standard placement procedure as recommended by the manufacturer was used. For the Rescue implants, a 5 mm external diameter trephine was used first (Fig 18). Trephines were initially rotated in a counter clockwise direction until the saw part of the trephine engaged the crest of the bone. The drilling was done in a clockwise direction. The osteotomy site was extended with a 5.4 mm diameter pilot drill. Implants were placed using the motor set at 25 Ncm, and, if necessary, manually with

the ratchet wrench. EZ Plus implants were placed according the following sequence. The implant site was marked with a lance drill. Drills with increasing diameters (2, 2.8 and 3.3 mm) were used to prepare the implant sites. Implant sites were slightly under-prepared and the surgical unit was set to a torque of 25 Ncm. In all cases, the heads of the implants were placed flush to bone levels. Resistance at implant insertion was recorded as <25 Ncm or >25 Ncm in this latter case the manual wrench was used to seat the implant. Cover screws were placed and a submerged technique was used. Flap closure was obtained with vicryl 4.0. Intra-oral radiographs (baseline) were made with the par-

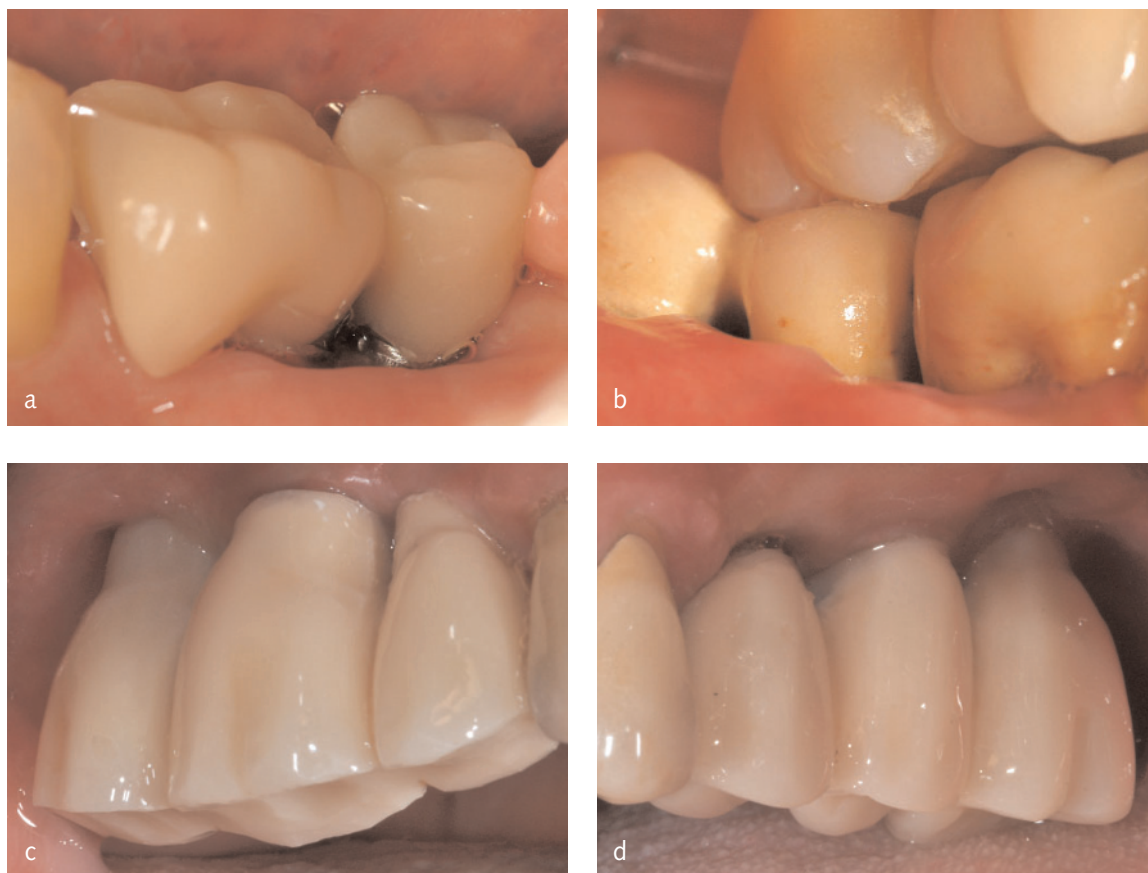

Fig 19 Four months after delivery of the provisional prostheses, definitive screw-retained metal-ceramic restorations rigidly joining the implants with occlusal surfaces in ceramic were delivered: a) prosthesis on short mandibular implants, b) prosthesis on long implants in vertically augmented mandible, c) prosthesis on short maxillary implants and d) prosthesis on long implants in augmented sinus.

alleling technique. In the case that the bone levels around the study implants were hidden or difficult to be estimated, a second radiograph was made. Ibuprofen 400 mg was prescribed to be taken 2 to 4 times a day during meals, as long as required. Patients were instructed to use 0.2 chlorhexidine mouthwash for 1 minute twice a day for 2 weeks, to have a soft diet for one week, and to avoid brushing and trauma on the surgical sites. No removable prosthesis was allowed. Sutures were removed after 10 days.

Prosthetic and follow-up procedures

After 3 months of submerged healing, implants were exposed, and an impression with the pick-up impression copings was taken using a polyether material (Impregum™, 3M ESPE, Neuss, Germany) and a customised resin impression tray. The vertical dimension

was registered and models were made with class 4 precision plaster and mounted in a standard articulator. Four months after placement, implants were manually tested for stability and provisional screw-retained reinforced acrylic restorations rigidly joining the implants were delivered on temporary abutments. The occlusal surfaces were in slight contact with the opposite dentition. Intraoral radiographs of the study implants were taken. Four months after delivery of the provisional prostheses, implants were manually tested for stability and definitive screw-retained metal-ceramic restorations rigidly joining the implants with occlusal surfaces in ceramic were delivered on gold UCLA abutments (Fig 19). Intraoral radiographs of the study implants were taken (Fig 20).

Patients were enrolled in an oral hygiene program with recall visits every 4 months for the entire duration of the study.

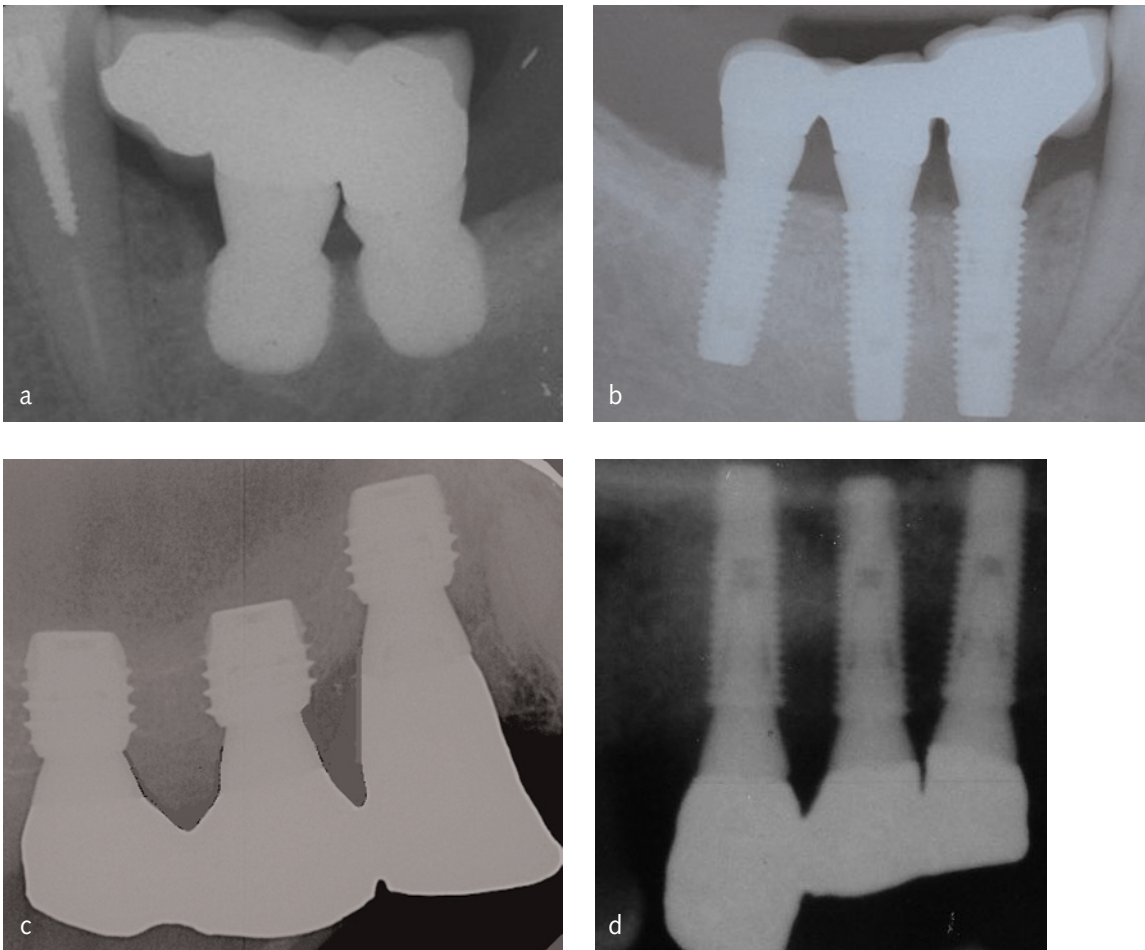


Fig 20 Intraoral radiographs of the study implants at delivery of the definitive restorations: a) short implants in mandible, b) long implants in augmented mandible, c) short maxillary implants and d) long implants in augmented sinus.

Follow-ups were conducted by an independent outcome assessor (GP) together with the surgical operator (PF).

■ Outcome measures

The present study tested the null hypothesis that there were no differences between the two procedures against the alternative hypothesis of a difference. Outcome measures were:

- Prosthesis failure: planned prosthesis which could not be placed due to implant failure(s) and loss of the prosthesis secondary to implant failure(s).
- Implant failure: implant mobility and removal of stable implants dictated by progressive marginal bone loss or infection. Stability of each individual implant was measured after removing the

restorations at delivery of the provisional prostheses (4 months after implant placement), and at delivery of the definitive prostheses (4 months after delivery of the provisional prostheses) by tightening the abutment screws with the removed prostheses using a manual wrench with a 15 Ncm force. In the case of single implants, the metallic handles of 2 instruments were used to assess implant stability.

- Any biological or prosthetic complications.
- Time (days) needed to fully recover mental nerve sensitivity after the augmentation procedure (augmented group) and implant placement (both groups).
- Peri-implant marginal bone levels evaluated on intraoral radiographs taken with the paralleling technique at implant placement, at delivery of the provisional prosthesis, 1 and 5 years after load-

ing. Data on this outcome will be reported in future publications.

- Patient preference assessed 1 month after delivery of the provisional prostheses by an independent assessor asking the patients which treatment they preferred. The answer could be: *i*) the augmented site; *ii*) short implants; *iii*) none, both treatments were equally good; and *iv*) none, both treatments were equally bad. Patients could also express their comments.

■ Methodological aspects

One dentist (GP) not involved in the treatment of the patients performed all clinical and radiographic assessments without knowing group allocation, therefore the outcome assessor was blind, however the Bio-Oss augmented sites could be identified both clinically, when testing implant stability because of the different diameters, and on radiographs because they appeared more radiopaque and implants were different.

The patient preference for the procedure was considered to be the most important outcome measure, therefore, the sample size was calculated for patient preference based on a previous trial¹⁰ to detect a preference of one group over another against the alternative hypothesis that the treatments are equally preferred. This reduces to a simple one sample proportion scenario. A one group chi-square test with a 0.050 two-sided significance level will have 80% power to detect the difference between the Null hypothesis proportion of 0.500 and the Alternative proportion of 0.900 when the sample size is 10. The sample was increased by one third since it was hypothesised that patient preference would not be so definite in this trial and the 2 groups (upper and lower jaws) were kept separate since patients could have a different preference according to the location of the intervention. Thirty partially edentulous patients with bilateral posterior jaw atrophy were included: 15 patients were partially edentulous in the upper and 15 in the lower jaw.

A computer generated restricted randomisation list was created. Only one of the investigators (ME), not involved in the selection and treatment of the patients, was aware of the randomisation sequence and could have access to the randomisation list stored

in his password protected portable computer. The randomised codes were enclosed in sequentially numbered, identical, opaque, sealed envelopes. Envelopes indicating which site to augment were opened sequentially the same day of the augmentation procedure. Therefore, treatment allocation was concealed to the investigators in charge of enrolling and treating the patients.

All data analysis was carried out according to a pre-established analysis plan. A biostatistician with expertise in dentistry analysed the data, without knowing the group codes. The patient was the statistical unit of the analyses. Differences in the proportion of patients with prosthesis failures, implant failures, complications (dichotomous outcomes) and days needed to fully recover mental nerve sensitivity (data was dichotomised: day zero or not) were compared between the groups using the McNemar chi-square test. The preference data were analysed like binary data from a crossover trial. The methods of Curtin²⁰ were then used to calculate the odds ratio, 95% confidence interval and *P* value for preferring one intervention over the other. All statistical comparisons were conducted at the 0.05 level of significance.

■ Results

Sixty-seven patients were screened for eligibility, but 37 patients were not included in the trial for the following reasons: 23 patients did not have enough bone width; 4 patients did not have enough bone height; 7 patients were hesitant to receive short implants, 2 patients had radiotherapy for breast cancer and 1 was affected by osteoporosis. Thirty patients were considered eligible and were consecutively enrolled in the trial. All patients were treated according to the allocated interventions, no drop-outs occurred up to the insertion of the final prosthesis and the data of all patients was evaluated in the statistical analyses. The following deviations from the protocol occurred:

- EZ Plus implants 10 to 13 mm long, with a diameter of 4 mm were used at the augmented sites instead of the 10 mm long (or shorter if necessary) Rescue implants of 6 mm diameter.
- Three patients were not recruited despite not having any of the decided exclusion criteria. Two patients were excluded for having received irra-

diation for breast cancer and one patient due to osteoporosis.

Patients were recruited and subjected to bone augmentation procedures from July 2008 to January 2009. The last definitive prosthesis was inserted in September 2009. The follow-up of all patients was up to the delivery of the final prostheses, 4 months after implant loading.

The main baseline patient and intervention characteristics, divided by study group and location, are presented in Table 1 and Table 2, respectively. Sixty-eight implants were placed in the augmented group and 60 in the short implant group. There were no apparent significant baseline imbalances between the two groups.

	Mandibles (n=15)	Maxillae (n=15)
Females	11	6
Mean age at implant insertion (range)	56 (37–69)	56 (45–70)
Smokers	3 light	2 light + 1 heavy

Table 1 Patient characteristics for mandibles and maxillae.

The main results are summarised in Table 3. At abutment connection, one mandibular implant failed in the augmented group versus one maxillary implant in the short implant group. Consequently, the prosthesis could not be placed at the planned time, though the short implant was successfully replaced by one placed more distally and loaded. The differences in proportions of prosthesis and implant fail-

	Augmented (n=30)	Short implants (n=30)
Mandibular implants	30	30
Maxillary implants	38	34
Mandibular implants placed with < 25 Ncm torque	3 (in 2 patients)	1
Maxillary implants placed with < 25 Ncm torque*	8 (in 5 patients)	7 (in 6 patients)
Mean length of mandibular implants	10.4 mm	5 mm
Mean length of maxillary implants	12.4 mm	5 mm

*At bilateral sites in 4 patients

Table 2 Intervention characteristics for mandibles and maxillae.

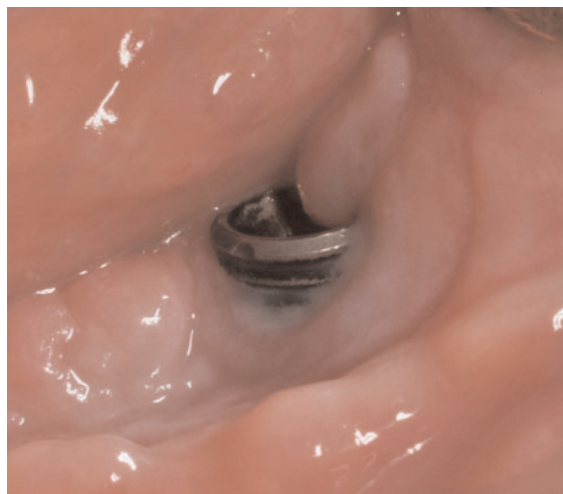	Augmented (n=30)	Short implants (n=30)
Failure to place at least 10 mm long in mandibles	5	Not applicable
Failure to place at least 10 mm long in maxillae	0	Not applicable
Failure to place mandibular prostheses when planned	1	0
Failure to place maxillary prostheses when planned	0	1
Failure of mandibular implants	1	0
Failure of maxillary implants	0	1
Complications (mandibles)	1	0
Complications (maxillae)*	1	3
Transient paraesthesia of the lip/chin after augmentation**	10	Not applicable
Transient paraesthesia of the lip/chin after implant placement**	1	1

* Two complications occurring in the same patient, one at each site.

** Bilateral transient paraesthesiae occurred in 2 patients, and 1 patient of the augmented group had paraesthesia twice at the same side (after the augmentation procedure and after implant placement).

Table 3 Summary of the main results.

Fig 21 Clinical picture of an 8.5 mm long mandibular implant placed in vertically augmented bone showing exposed threads due to bone loss possibly caused by infection. A dehiscence was noticed 10 days after implant placement that persisted until abutment connection when the implant was found to be mobile and removed.



ures were not statistically significant (P value not calculable). In the augmented group, one implant failed (in position 46) out of two 8.5-mm-long implants. A dehiscence was noticed 10 days after implant placement that persisted until abutment connection. Implant threads became exposed (Fig 21) possibly because of an infection. The implant has not been replaced yet. The failed 5 mm implant was placed with an insertion torque below 25 Ncm and occurred in the patient who had bilateral perforation of the maxillary sinus membranes.

Two complications (one mandibular dehiscence and one perforation of the sinus membrane) occurred in 2 patients of the augmented group versus 3 perforations in the short implant group. The difference in proportions was not statistically significant ($P = 1$). Two of the perforations at the 5 mm short implants were treated by placing a collagen barrier (Gingostat, OPOCRIN, Corlo, Italy). The other perforation appeared to close spontaneously after lifting the membrane, though the implant was found to be mobile at abutment connection. At augmented sites, the mandibular dehiscence was treated with 0.2% chlorhexidine gel and mouthwash, and the laceration of the sinus barrier was closed with a resorbable synthetic barrier (Inion, Tampere, Finland).

No permanent paraesthesia of the alveolar inferior nerve occurred, the longest lasting 3 days. More sites subjected to vertical augmentation had paraesthesia than those treated with short implants. In fact, 12 out of 15 sides in the short implant group (80%) had no impaired alveolar inferior nerve sensitivity versus 5 out of 15 in the augmented group (33%) (difference in proportion = 0.47; $P < 0.001$; 95% CI of the difference

0.15 to 0.78). Only one patient of the augmented group had a paraesthesia after implant placement (for 2 days).

Though not considered complications, the following events should be reported: in 5 patients after vertical bone augmentation of the mandible there was not sufficient bone to place the planned 10-mm-long implants and 7- to 8.5-mm-long implants had to be used instead. Two patients of the 5 mm short mandibular group had their alveolar inferior nerve exposed after the use of the trephine. A collagen membrane (Gingostat) was placed over the nerve and these patients had 1 and 2 days of altered nerve sensation. Ten patients (4 mandibles and 6 maxillae) out of 30 of the 5 mm group had submerged implants become exposed within 15 days after placement versus 5 patients in the mandible of the vertically augmented group.

There was no statistically significant difference in patient preference assessed one month after delivery of the provisional prostheses ($P = 1$). In the mandible, 11 patients had no preference, rating both procedures as acceptable, 2 patients preferred the short implants whereas 2 patients preferred the longer implants placed in an augmented mandible. All 15 patients expressed no preference for the procedures in the upper jaw, rating both procedures as acceptable. Six patients expressed the following comments. Four of the patients were operated in the mandible. Two patients preferred the short implants because the vertical augmentation procedure was felt to be long and the post-operative phase painful, whereas 2 patients preferred long implants placed in the augmented bone because the trephine drill resulted in an unpleasant, and in one case painful, sensation. The 2 patients operated on in the maxilla commented that the surgical time and post-operative discomfort was minimal at both sites. After the placement of 5 mm short mandibular implants, 3 patients asked to postpone implant placement on the other side. The contra-lateral implant placement procedure was implemented after 7 to 10 days.

■ Discussion

This trial was designed to assess whether 5-mm-long implants of 6 mm diameter could be a possible alter-

native to rehabilitate atrophic posterior jaws with implant-supported partial fixed prostheses. As control procedures it was decided to use augmentation procedures tested in other trials: vertical bone augmentation with interpositional blocks of anorganic bovine bone^{10,19} for atrophic mandibles and 2-stage sinus lift with lateral window approach using 100% bone substitute¹². All tested techniques were able to achieve the planned goal, however some different trends were noticed. In mandibles, despite patients not having a definite preference for any of the procedures tested, statistically more transient paraesthesia was observed in the augmented group. By placing short implants, the treatment period could be shortened by 4 months and the only implant failure occurred in the augmented group. In 5 patients (33%), the vertical augmentation procedure did not obtain sufficient height to place 10 mm implants and shorter implants (7 and 8.5 mm) had to be used instead. The augmentation procedure is also more technically demanding than placing short implants. Therefore, taking all these findings together, which are in agreement with the results of previous RCTs^{19,21} and a systematic review³, it is possible to suggest that short implants may be a more effective intervention than vertical augmentation of mandibles at least in the short-term, whereas the long-term prognosis remains unknown. The only unexpected finding was that patients did not express preference for either of the 2 tested procedures. While it is easy to understand that the more invasive augmentation procedure was not appreciated by 2 patients, 2 other patients expressed the opposite preference preferring the augmentation procedure to short implants. According to our qualitative interpretation of the patient comments it appears that the reason for this was the unpleasant feeling of the trephine drill used to prepare the implant sites. In addition, 3 patients, after having the short implants placed, asked to postpone implant placement of the other site. Unfortunately, the clinician deviated from the original protocol placing smaller diameter implants at augmented sites, not allowing for a more direct comparison of the 2 procedures. In fact, it is possible to speculate that, by using short implants of smaller diameters placed after traditional osteotomy site preparation, patient preference could have been different.

There is an additional issue to consider when interpreting the patient preference data. Unfortunately, at

protocol stage it was decided to first operate on the side to be augmented, wait for 4 months and then to place implants simultaneously at both sites so to facilitate the follow-up procedures. However, with this study design, patients may have not perceived the benefit of having the prostheses supported by short implants loaded 4 months before the other prostheses. This may have skewed preference data, which should be interpreted with caution.

The outcome in the maxilla is more difficult to interpret. Patients had no preference for any of the procedures, though the patient treated with the sinus lift procedure required one additional surgical intervention and treatment time was 4 months longer. Complications were minor at both sites, the only failed implant belonged to the 5-mm-long group. Another recent RCT¹⁶ compared 8-mm-long hydroxyapatite coated implants placed in crestally augmented maxillary sinuses with longer implants placed in sinuses augmented with the lateral approach technique with 50% particulated autogenous bone and 50% Bio-Oss, early loaded at 45 days post-placement. One year after loading, there were no statistically significant differences, but more implants failed and serious complications occurred in the group augmented with the lateral window approach to receive longer implants. It is difficult to extrapolate any evidence-based clinical suggestion based on the little patient data available, but it may be possible that a residual bone height of 4 to 6 mm below the maxillary sinus could be successfully rehabilitated with short implants alone or with longer implants placed after a mini-sinus lift procedure with a crestal approach. Studies with much larger sample sizes are needed to identify which is the more effective procedure for treating atrophic posterior maxillae.

Among the main limitations of the present investigation was the small sample size, though sufficient to provide significant results regarding the recovery of mental nerve function. Larger trials are needed to explore the matter in more detail. Another limitation could be a possible bias in patient preference since patients received both prostheses at the same time. With this design, patients may not have perceived that short implants could be loaded 4 months in advance. An additional trial in which one side is augmented and the other treated with short implants in the same surgical session would be needed to clarify

this issue. The use of a 2-stage lateral window approach to lift the maxillary sinus could have been another limitation. Ideally, a more conservative procedure such as a 1-stage lateral window procedure or even a crestal approach could have been used, since in a recent RCT, 8-mm-long implants placed in a crestally elevated sinus with a residual bone height of 3 to 6 mm yielded slightly better success rates, even when loaded only 45 days after placement, than longer implants placed in a sinus augmented with a lateral window technique¹⁶.

On the other hand, all treated patients were accounted for with no exclusions and all assessments were done by an independent and blinded assessor, though the assessor could recognise the augmented sites since implants had a smaller diameter, were longer and Bio-Oss tended to appear more radiopaque on radiographs than normal bone. Another aspect that should be mentioned is that the trial was originally designed to test identical implants of different lengths in a split-mouth design and this was done to minimise factors which could influence the final results. While this would have made direct comparisons (patient preference and radiographic evaluations) more valid, the treating clinician felt that for patient benefit it was more appropriate to use a more conventional implant. It is interesting to observe that in another recent similar trial¹⁶, the surgeon used 8-mm-long implants with a wider diameter than those of the longer implants placed in augmented sinus. The role of the implant diameter in short implants is unknown, though clinicians tend to compensate the lack of height by using implants with a wider diameter. It would be useful to study the role of implant diameter for short implants. The Rescue system was chosen since it had all the heights we wished to test (5 to 10 mm), though lacked diameters smaller than 6 mm. Finally, another remark is that the trial was designed starting with the augmentation procedure, but this was a compromise made during protocol design for a split-mouth trial. In fact, all patients had the augmentation procedure performed first and after 4 months implants were placed bilaterally. Consequently, patients did not have the possibility to receive the prosthesis on the short implants 4 months before and this may have affected their preference, since the time advantage of short implants was lost.

The good performance of 5-mm-long implants is difficult to be explained in view of a systematic review that reported a 10% failure rate for 7-mm-long implants¹. It might be speculated that the large implant diameter might have played an important role in the success, though this is just a hypothesis and not a fact, which therefore needs to be investigated with proper clinical trials. At the planning stage it was discussed with the implant manufacturer whether implants with a smaller diameter could be used, unfortunately this option was not available and this factor severely limited patient recruitment into the trial. It was not easy to find patients with 8 mm (bilaterally) of bone thickness at posterior jaws. Twenty-seven patients, which is about one out of two, had to be excluded because of insufficient bone width. In future clinical trials, it would be very useful to test the efficacy of very short implants as used in this trial but with smaller diameters, 4 to 5 mm, in order to know whether patients with 5 to 7 mm of bone width could be successfully treated without undergoing more invasive bone augmentation procedures. It would be also interesting to test alternative bone augmentation techniques including one-stage mini-sinus lift procedures with a crestal approach^{16,22-24}. The surgeon was experienced with all tested techniques and this factor might limit the extrapolations of the present results, however all procedures were tested in real clinical conditions, therefore the results of the present trial can be generalised with confidence to a wider population with similar characteristics.

■ Conclusions

All techniques achieved good and similar results, however, when the residual bone height over the mandibular canal is 5 to 7 mm, 5 mm short implants could be a preferable choice since the treatment was faster, cheaper and associated with less morbidity than vertical bone augmentation. With respect to atrophic maxillae with 4 to 6 mm of residual bone height below the maxillary sinus, short implants allowed patients to have their prostheses 4 months earlier than a sinus lift procedure, but it is unclear whether they could be at higher risk for early implant failure. Unfortunately, only a few patients have a sufficient bone width (at least 8 mm) to accommodate implants with a 6 mm

diameter. These preliminary results must be confirmed by longer follow-ups of 5 years or more in order to monitor the performance of short implants over time. Short implants with diameters of 4 to 5 mm ought to be evaluated as well.

Acknowledgements

MegaGen Implant Co. Ltd. Gyeongbuk, South Korea is acknowledged for generously donating the implants and prosthetic components used in the present investigation.

References

1. das Neves FD, Fones D, Bernardes SR, do Prado CJ, Neto AJ. Short implants - an analysis of longitudinal studies. *The International Journal of Oral and Maxillofacial Implants* 2006;21:86-93.
2. Renouard F, Nisand D. Impact of implant length and diameter on survival rates. *Clinical Oral Implants Research* 2006;17 Suppl 2:35-51.
3. Esposito M, Grusovin MG, Felice P, Karatzopoulos G, Worthington HV, Coulthard P. Interventions for replacing missing teeth: horizontal and vertical bone augmentation techniques for dental implant treatment. *Cochrane Database of Systematic Reviews* 2009.
4. Esposito M, Grusovin MG, Kwan S, Worthington HV, Coulthard P. Interventions for replacing missing teeth: bone augmentation techniques for dental implant treatment. *Cochrane Database of Systematic Reviews* 2008: Chichester, UK: John Wiley & Sons, Ltd.
5. Chiapasco M, Romeo E, Casentini P, Rimondini L. Alveolar distraction osteogenesis vs. vertical guided bone regeneration for the correction of vertically deficient edentulous ridges: a 1-3-year prospective study on humans. *Clinical Oral Implants Research* 2004;15:82-95.
6. Chiapasco M, Zaniboni M, Rimondini L. Autogenous onlay bone grafts vs. alveolar distraction osteogenesis for the correction of vertically deficient edentulous ridges: a 2-4-year prospective study on humans. *Clinical Oral Implants Research* 2007;18:432-440.
7. Merli M, Migani M, Esposito M. Vertical ridge augmentation with autogenous bone grafts: resorbable barriers supported by osteosynthesis plates versus titanium-reinforced barriers. A preliminary report of a blinded, randomized controlled clinical trial. *The International Journal of Oral Maxillofacial Implants* 2007;22:373-382.
8. Fontana F, Santoro F, Maiorana C, Iezzi G, Piattelli A, Simion M. Clinical and histologic evaluation of allogenic bone matrix versus autogenous bone chips associated with titanium-reinforced e-PTFE membrane for vertical ridge augmentation: a prospective pilot study. *The International Journal of Oral Maxillofacial Implants* 2008;23:1003-1012.
9. Bianchi A, Felice P, Lizio G, Marchetti C. Alveolar distraction osteogenesis versus inlay bone grafting in posterior mandibular atrophy: a prospective study. *Oral Surgery, Oral Medicine, Oral Pathology, Oral Radiology and Endodontics* 2008;105:282-292.
10. Felice P, Marchetti C, Piattelli A, Pellegrino G, Checchi V, Worthington H, et al. Vertical ridge augmentation of the atrophic posterior mandible with interpositional block grafts: bone from the iliac crest versus bovine anorganic bone. Results up to delivery of the final prostheses from a split-mouth, randomised controlled clinical trial. *European Journal of Oral Implantology* 2008;1:183-187.
11. Wannfors K, Johansson B, Hallman M, Strandkvist T. A prospective randomized study of 1- and 2-stage sinus inlay bone grafts: 1-year follow-up. *The International Journal of Oral and Maxillofacial Implants* 2000;15:625-632.
12. Hallman M, Sennerby L, Lundgren S. A clinical and histologic evaluation of implant integration in the posterior maxilla after sinus floor augmentation with autogenous bone, bovine hydroxyapatite, or a 20:80 mixture. *The International Journal of Oral and Maxillofacial Implants* 2002;17:635-643.
13. Raghoebar GM, Schortinghuis J, Liem RS, Ruben JL, van der Wal JE, Vissink A. Does platelet-rich plasma promote remodeling of autologous bone grafts used for augmentation of the maxillary sinus floor? *Clinical Oral Implants Research* 2005;16:349-356.
14. Szabó G, Huys L, Coulthard P, Maiorana C, Garagiola U, Berabás J, et al. A prospective multicenter randomized clinical trial of autogenous bone versus beta-tricalcium phosphate graft alone for bilateral sinus elevation: histologic and histomorphometric evaluation. *The International Journal of Oral and Maxillofacial Implants* 2005;20:371-381.
15. Schaaf H, Streckbein P, Lendeckel S, Heidinger KS, Rehmann P, Boedeker RH, et al. Sinus lift augmentation using autogenous bone grafts and platelet-rich plasma: radiographic results. *Oral Surgery, Oral Medicine, Oral Pathology, Oral Radiology and Endodontics* 2008;106:673-678.
16. Cannizzaro G, Felice P, Leone M, Viola P, Esposito M. Early loading of hydroxyapatite coated implants in the atrophic posterior maxilla: lateral sinus lift with autogenous bone and Bio-Oss versus crestal mini-sinus lift and 8 mm implants. A randomized controlled clinical trial. *European Journal of Oral Implantology* 2009; :25-38.
17. Bettega G, Brun JP, Boutonnat J, Cracowski JL, Quesada JL, Hegelhofer H, et al. Autologous platelet concentrates for bone graft enhancement in sinus lift procedure. *Transfusion* 2009;49:779-785.
18. Felice P, Scarano A, Pistilli R, Checchi L, Piattelli M, Pellegrino G, et al. A comparison of two techniques to augment maxillary sinuses using the lateral window approach: rigid synthetic resorbable barriers versus anorganic bovine bone. Five-month post-loading clinical and histological results of a pilot randomized controlled clinical trial. *European Journal of Oral Implantology* 2009;2: in press.
19. Felice P, Cannizzaro G, Checchi V, Pellegrino G, Censi P, Esposito M. Vertical bone augmentation versus 7 mm long dental implants in posterior atrophic mandibles. A randomized controlled clinical trial. *European Journal of Oral Implantology* 2009;2:7-20.
20. Curtin F, Elbourne D, Altman DG. Meta-analysis combining parallel and cross-over clinical trials. II: Binary outcomes. *Statistics in Medicine* 2002;21:2145-2159.
21. Stellingsma K, Raghoebar GM, Meijer HJ, Stegenga B. The extremely resorbed mandible: a comparative prospective study of 2-year results with 3 treatment strategies. *The International Journal of Oral and Maxillofacial Implants* 2004;19:563-577.
22. Tatum HJ. Maxillary and sinus implant reconstructions. *Dental Clinics of North America* 1986;30:207-229.
23. Summers RB. A new concept in maxillary implant surgery: the osteotome technique. *Compendium* 1994;15:152-158.
24. Cosci F, Luccioli M. A new sinus lift technique in conjunction with placement of 265 implants: a 6-year retrospective study. *Implant Dentistry* 2000;9:363-368.